

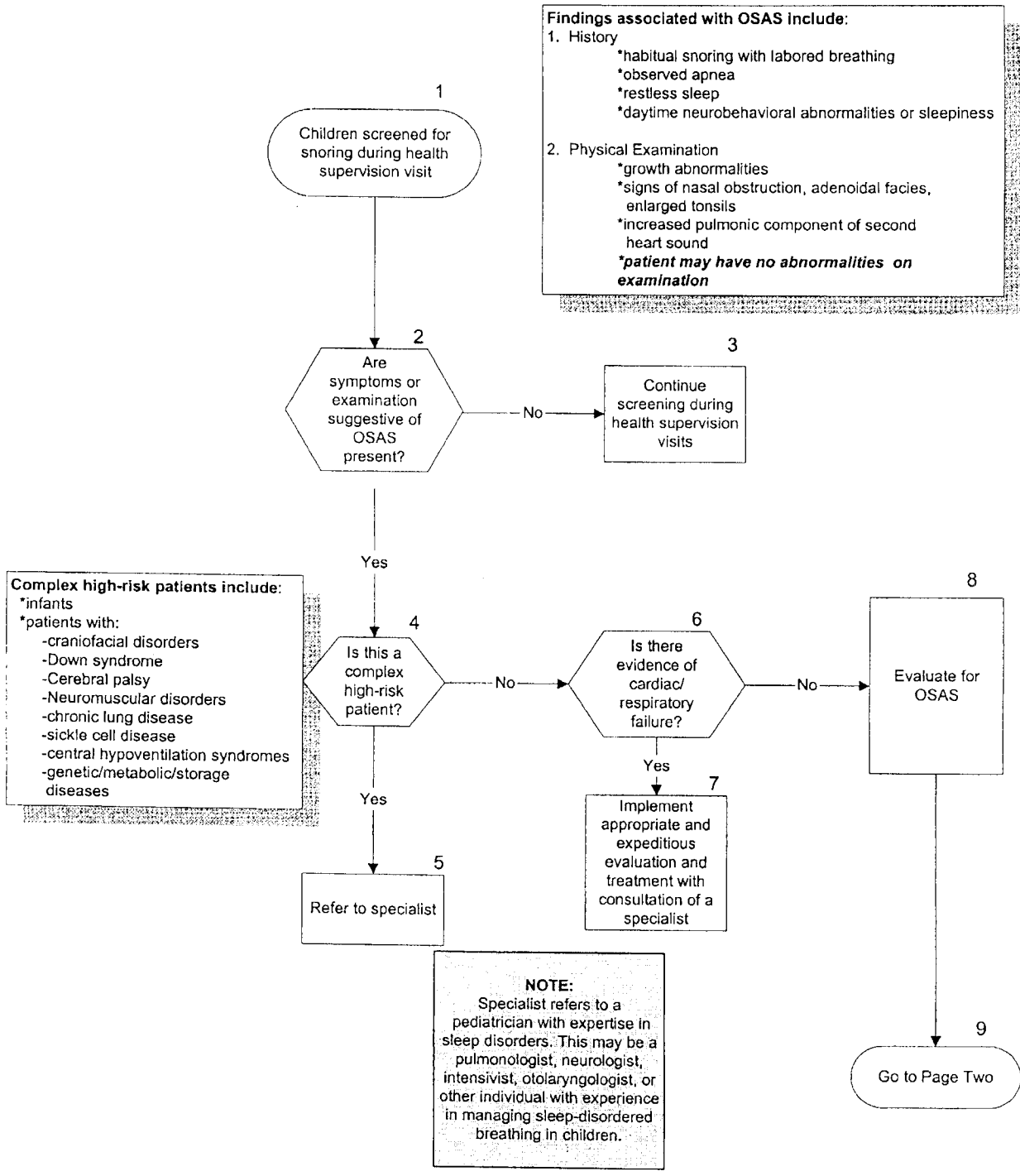Fig 1. Diagnosis and management of uncomplicated childhood OSAS.

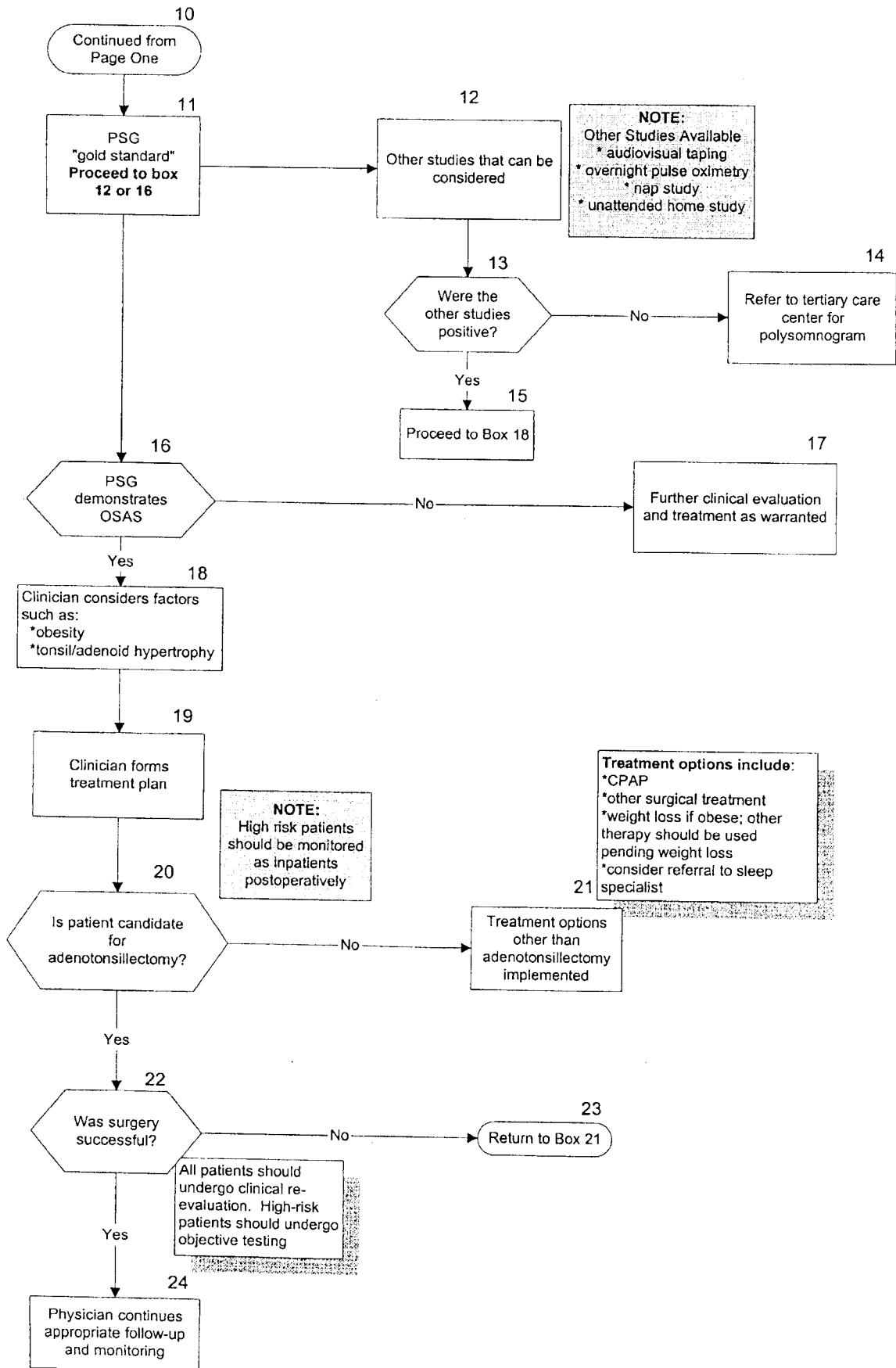


Fig 1. (continued)